

PATIENT PRESENTING CLINICAL SIGNS

Stassi Klem Limping right rear, R/O partial acl tear.
Abnormal PE/Chem/CBC/UA Results: No laxity on palpation under anesthesia

SPECIES RADIOGRAPHIC STUDY OF THE RIGHT STIFLE

Canine Mediolateral and craniocaudal views of the right stifle joint, totaling two images available for review.

RADIOGRAPHIC FINDINGS

BREED Moderate articular soft tissue swelling of the right stifle joint is seen.

Bulldog Mix A moderate amount of periarticular osteophytes at the patella base, trochlear ridges and plateau margins is present.

SEX The patella is normally in position with no visible tibial subluxation.

FS No cranial tibial thrust is observed radiographically.

AGE There is no evidence of traumatic osseous injury or aggressive bone disease.

RADIOGRAPHIC DIAGNOSIS

6yr

INTERPRETED BY

- Moderate right stifle osteoarthritis with articular swelling
- No radiographic evidence of acute fracture, subluxation or tibial thrust

Nele Eley (Ondreka),
DVM Dr. med. vet.,
DipECVDI

INTERPRETATION OF FINDINGS & FURTHER RECOMMENDATIONS

The radiographic study reveals moderate right stifle osteoarthritis consistent with chronic degenerative changes, possibly secondary to cranial cruciate ligament injury. Partial injury is considered more likely than complete injury owing to the lack of instability under a sedation. Consider ultrasound or MRI if confirmation of partial cruciate ligament injury or meniscal injury is clinically relevant.

HOSPITAL NAME

Hamburg Veterinary
Clinic

REFERRING VET

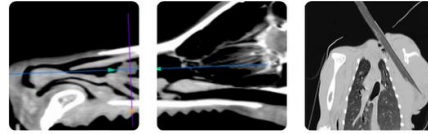
Dr Martens

INVOICE

22942

DATE

11/12/2025



PATIENT

Stassi Klem

SPECIES

Canine

BREED

Bulldog Mix

SEX

FS

AGE

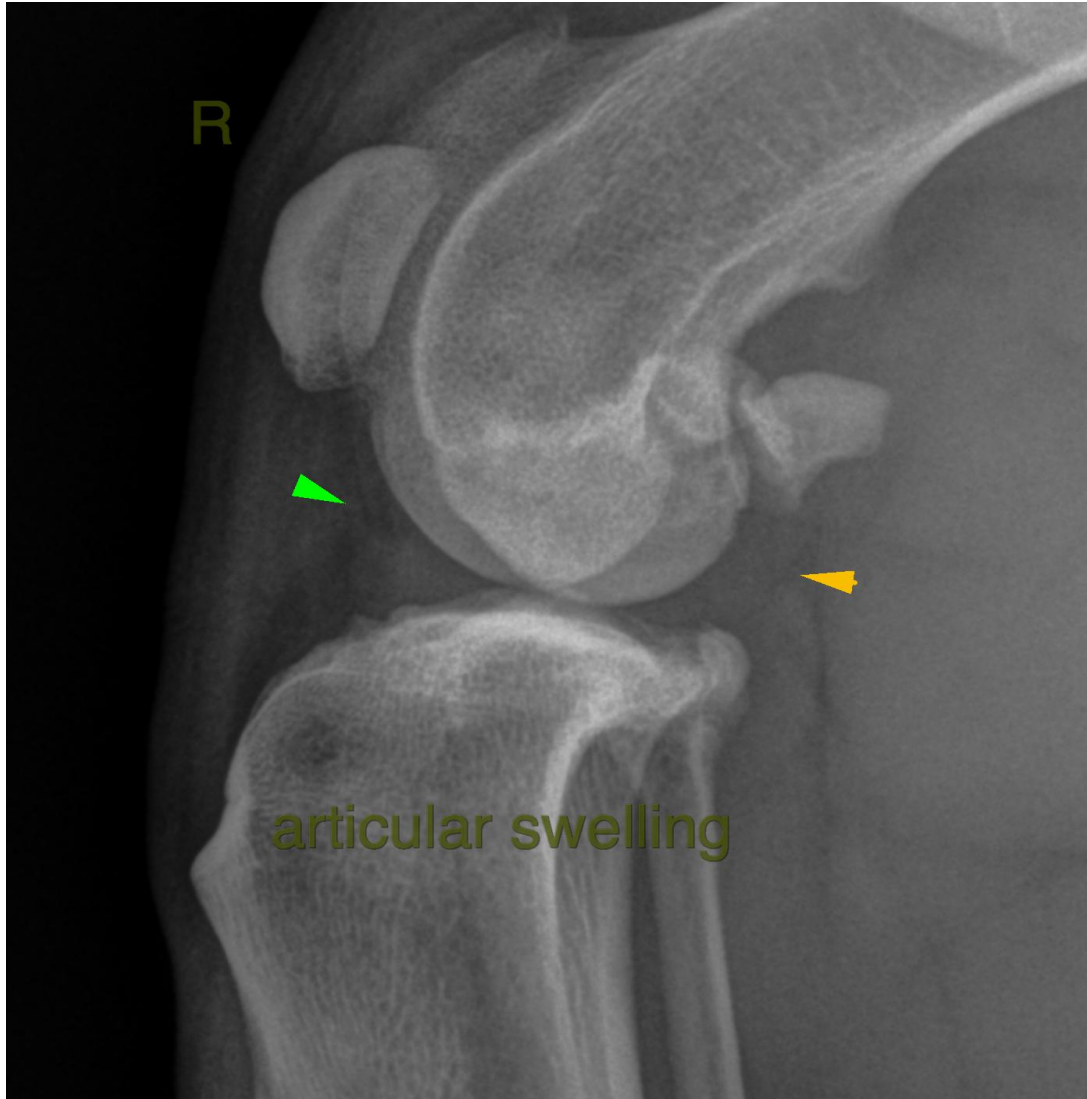
6yr

INTERPRETED BY

Nele Eley (Ondreka),
DVM Dr. med. vet.,
DipECVDI

HOSPITAL NAME

Hamburg Veterinary
Clinic



REFERRING VET

Dr Martens

The information and recommendations provided are based on the images presented by the referring veterinarian. No evaluation can be communicated regarding pathology that was not visible in the image/video clips provided.

Thank you for this referral. If the clinical or image interpretation does not parallel your findings or if I can be of any further assistance please contact me.

INVOICE

22942

Nele Eley (Ondreka), DVM, Dr. med. vet., DipECVDI
European Specialist in Veterinary Diagnostic Imaging, Cert. Radiology,
Senior lecturer University of Giessen/Germany, Veterinary Faculty, Department of Radiology.

DATE

info@sonopath.com

11/12/2025



PATIENT

Stassi Klem

SPECIES

Canine

BREED

Bulldog Mix

SEX

FS

AGE

6yr

INTERPRETED BY

Nele Eley (Ondreka),
DVM Dr. med. vet.,
DipECVDI

HOSPITAL NAME

Hamburg Veterinary
Clinic

REFERRING VET

Dr Martens

INVOICE

22942

DATE

11/12/2025